

PHARYNGEAL DERMoids ("HAIRY POLYPS") AS ACCESSORY AURICLES

CAPT DENNIS K. HEFFNER, MC, USN
WASHINGTON, DC

COL DAVID G. SCHALL, USAF, MC
TACOMA, WASHINGTON

LCDR LESTER D. R. THOMPSON, MC, USNR
WASHINGTON, DC

VIRGINIA ANDERSON, MD
BROOKLYN, NEW YORK

The purpose of this study is to clarify the origin and nature of so-called hairy polyps or dermoids of the pharynx, which are often thought to be a variant of pharyngeal teratoma. For this purpose, a case is reported of a dermoid polyp involving the middle ear of an infant, the features of multiple examples of pharyngeal dermoid polyps and teratomas received for consultation by the Armed Forces Institute of Pathology are examined, and selected pertinent reports from the literature are reviewed. All three means are used to support the conclusion that these lesions are choristomatous developmental anomalies arising from the first branchial cleft area and that they essentially represent heterotopic accessory "ears" (auricles) without the growth potential of a teratoma.

KEY WORDS — accessory auricle, choristoma, dermoid, middle ear, pharynx, teratoma.

INTRODUCTION

Arnold¹ in 1888 described four types of congenital pharyngeal malformations: 1) epignathus, with grossly very well-developed anatomic structures, 2) pharyngeal teratoma, 3) pharyngeal "teratoid," with poorly differentiated structures or tissues, and 4) pharyngeal dermoid. Category 1 is the type of abnormality that would suggest a maldeveloped twin, or fetus in fetu, as the genesis of the malformation. Category 2 would seem to correspond to what might be called a conventional teratoma, or the type usually encountered in various anatomic locations. Category 3 is one that is difficult to clearly delineate within more modern ideas of pathologic classification. Category 4 is the subject of this present study.

Schwalbe² in 1907 had a slightly different list of four categories, all considered subcategories of epignathus: 1) pharyngeal masses with remarkably well-differentiated structures, including umbilical cord formation (these cases must be "vanishingly" rare), 2) masses with grossly well-differentiated organoid structures, 3) "conventional" teratoma, and 4) dermoids.

While Arnold¹ apparently did not explicitly denote the pharyngeal dermoid as a variant of teratoma, some subsequent classifications (eg, especially, Schwalbe's²) implied that the pharyngeal dermoids are within the spectrum of teratoma; ie, they could be construed as a limited form of teratoma. Some authors in recent decades have not labeled the pharyn-

geal dermoids as teratomas, but rather, have considered them to be choristomas.³ However, there are authors who still imply that hairy polyps are a limited teratoma.⁴

Although admittedly not a profound clinical question, determining that these malformations are not teratomas (and therefore do not have the growth potential of a teratoma and certainly no malignant potential, in contrast to some teratomas) is clinically relevant. The evidence presented herein that supports a specific developmental provenance for pharyngeal dermoid polyps is probably of some academic interest for furthering the detailed knowledge of these specific developmental anomalies.

CASE REPORT

A 16-month-old girl was evaluated at an otolaryngology clinic in the interior of Alaska for recurrent otitis media and right otorrhea. She had a history of recurrent otitis media (mostly on the right side) since age 7 months (>12 episodes). Her language development had been appropriate for age. She had no prior surgery or hospitalizations and was on no medication. The examiners noted a soft tissue mass filling the medial half of the external ear canal. An outpatient clinic biopsy revealed keratin, suggestive of a cholesteatoma. A computed tomography (CT) scan demonstrated a mass filling the right external auditory canal and middle ear, extending into the mastoid, hypotympanum, protympanum, and pterygomaxillary

From the Otolaryngic and Endocrine Pathology Department, Armed Forces Institute of Pathology, Washington, DC (Heffner, Thompson), the Otolaryngology-Head and Neck Surgery Service, Madigan Army Medical Center, Tacoma, Washington (Schall), and the Department of Pathology, State University of New York Health Sciences Center, Brooklyn, New York (Anderson). The opinions or assertions contained herein are the private views of the authors and are not to be construed as reflecting the opinions of the Department of the Navy, Department of the Army, Department of the Air Force, or Department of Defense.

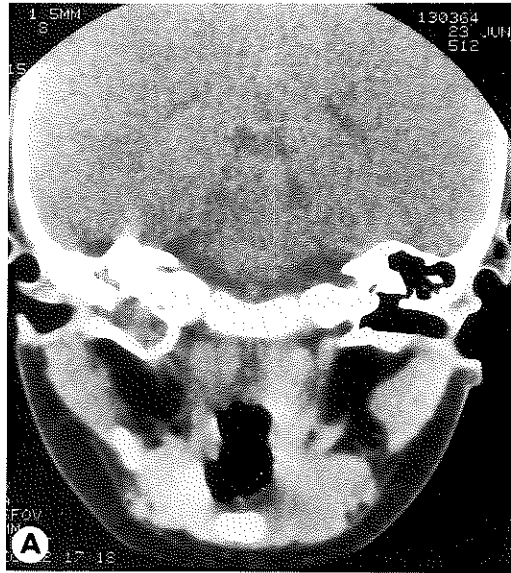
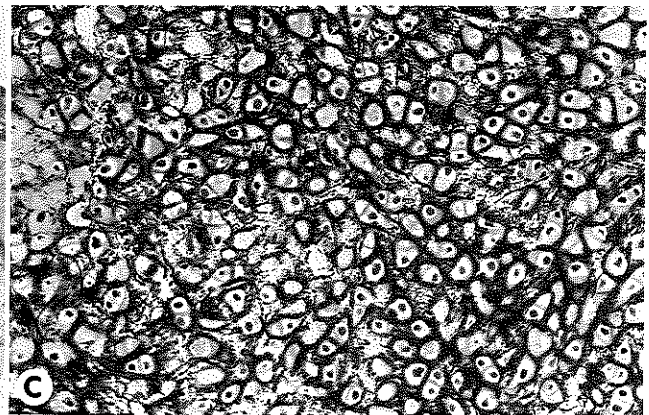
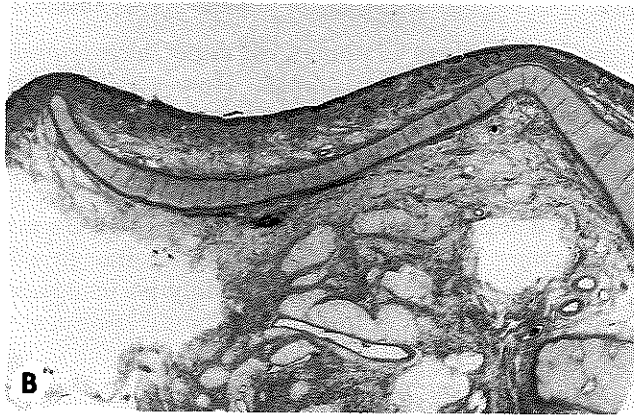

Fig 1. Case reported herein. A) Computed tomogram demonstrating tissue mass within right tympanic space. B) Low-power photomicrograph of middle ear mass showing cartilage plate, approximately horizontal, near upper surface of tissue. C) High-power photomicrograph of cartilage plate stained for elastic tissue (Movat stain); black staining surrounding cells indicates abundant elastic fibers.



space, and which apparently exposed the carotid artery. There appeared to be dehiscence of the middle fossa dura. The patient was then transferred to Madigan Army Medical Center (MAMC) for further evaluation.

Examination at MAMC confirmed the above findings. Facial nerve function was normal. Cranial nerves II through XII were intact except for cranial nerve VIII on the right. There was no nystagmus noted. Audiometric testing revealed speech awareness thresholds at 20 dB hearing level for the better-hearing ear. Immittance was normal in the left ear and abnormal on the right. Additional CT views (Fig 1A) confirmed the previously noted findings, except that the carotid artery appeared to be covered.

The patient was taken to the operating room, where multiple biopsies of the external ear canal mass were performed. Frozen section results revealed keratin material without evidence of rhabdomyosarcoma. The soft tissue mass was then debulked to the level of the tympanic membrane. No tympanic membrane was found; however, a bar of horizontally situated cartilage similar to tragal cartilage was noted at the

level of the annulus. A mastoidectomy was then performed. Squamous debris was encountered at the level of Koerner's septum, filled the medial mastoid, extended into the middle ear, and abutted the mass. At this point, because of the extensive squamous debris, a canal wall down procedure was undertaken. The incus and malleus were noted to be displaced superiorly by the mass. The mass was then mobilized and it seemed to be attached to (and perhaps arising from) the area of the tympanic annulus; it was grasped and rotated out of the middle ear, hypotympanum, and pterygomaxillary space. The carotid artery was covered and the stapes superstructure was intact except for the capitulum. No dural dehiscence was noted. There was no aberrancy of the facial nerve. A meatotoplasty was performed and the procedure terminated.

Pathologic examination revealed that the lesion was not a cyst, but rather, was a solid polypoid structure. On the histologic slides, the specimen contained a well-formed cartilage plate that was thin and elongated, measuring approximately 1.0 mm in width and approximately 18 mm in extent (Fig 1B).

The cartilage was elastic cartilage (manifesting elastic fibers on an elastic tissue stain) and very much resembled auricular cartilage (Fig 1C). Surrounding the cartilage plate was adipose tissue similar to subcutaneous tissue, and surrounding this and lining the surface of the specimen was skin (dermis and epidermis with adnexal structures, including hair appendages). The histologic similarity to auricular tissue was clearly apparent — especially the conformation of the cartilage.

The patient has done well for 12 months postoperatively without complications.

ADDITIONAL MATERIALS AND METHODS

Eight cases of pharyngeal dermoid polyps and four cases of pharyngeal teratomas retrieved from the Armed Forces Institute of Pathology (AFIP) consultation files were studied. The histologic material was scrutinized for the details of tissue composition, especially the exact structure of the cartilage, including the size and general conformational outline and whether or not there was evidence of elastic cartilage. The AFIP material was also used to compare the tissues of pharyngeal teratomas with those of hairy polyps, with particular attention once again given to cartilage. Also, comparison of the histologic features of the hairy polyps was made to the features of developing fetal auricles furnished by one of the authors (V.A.).

Literature reports of hairy polyps were scrutinized for the location of origin of the lesions, the gross appearance, associated malformations, and the details of tissue composition. In the last instance, the exact structure of the cartilage was considered apposite, including the size and general conformational outline and whether or not there was evidence of elastic cartilage.

RESULTS

The literature review indicated that our hypothesis that pharyngeal dermoids are accessory auricles is not exactly new. A few reports^{5,6} described hairy polyps that have a gross resemblance to (malformed) auricles. The logical inference was made in these reports that the hairy polyps were probably of first or second branchial arch origin, and one report⁶ explicitly labeled the pharyngeal lesion as an accessory auricle. However, these reports (including the latter) did not explicitly or fully develop the argument that pharyngeal hairy polyps in general are accessory auricles. Moreover, these reports are few, and the idea that pharyngeal hairy polyps might be accessory auricles is certainly not widely known.

In the literature, the term dermoid is often consid-

ered synonymous with dermoid cyst. This is reasonable, since dermoid lesions in most parts of the body (including the older term of dermoid cyst of the ovary, which is now recognized to more accurately be a benign cystic teratoma) are indeed cysts. It seems to be tacitly assumed by some that all dermoid lesions are cysts. This can be seen in reports of dermoids that are entitled with "dermoid cyst," and yet the description of the lesion does not seem to indicate a cystic lesion.^{7,8} It is clear from the literature that pharyngeal dermoids actually are not dermoid cysts, but rather, are solid polypoid lesions.

Although pharyngeal dermoids can arise from the soft palate (nasopharyngeal surface) or in the oropharynx, including the tonsillar region, a majority of these malformations occur laterally in the vault of the nasopharynx and therefore are not far from a eustachian tube orifice. Some even appear to be arising within the eustachian tube and protruding from it.^{8,9} There are reports of dermoids entirely confined to the eustachian tube.¹⁰

There are also a few reports of dermoids of the middle ear or mastoid area.^{7,11-13} It is often difficult to tell from the reported information whether the lesion was solid or truly cystic. At least one may have been a small cyst,¹³ but others were more likely solid polypoid lesions.⁷ In at least one instance the lesion appeared to arise from the eustachian tube and extended into the tympanic cavity.¹¹

The very large majority of pharyngeal, eustachian tube, or tympanic dermoid polyps occur in patients who have normal auricles. However, there are a few reports of patients with pharyngeal dermoid polyps and associated malformations of the auricle.^{12,14}

Since pathologic material was available in the AFIP cases, it could be examined in more detail (including elastic tissue stains on cartilage) than is generally available in literature reports, which often do not have histologic pictures or information regarding the type of cartilage. Examination of our cases of dermoid polyps revealed most to have prominent cartilage within the mesenchymal tissues. Usually the cartilage was in the form of an elongated or curved plate of relatively uniform thickness and was approximately as thick as normal auricular cartilage (Fig 2). Elastic cartilage was not well developed in most specimens, but in two cases it was extremely well developed, with striking elastic fibers manifested with an elastic fiber stain. The strong resemblance to auricular cartilage was most impressive. For the eight cases examined, the degree of elastic cartilage differentiation could not be significantly correlated with the age of the patient. Comparison of

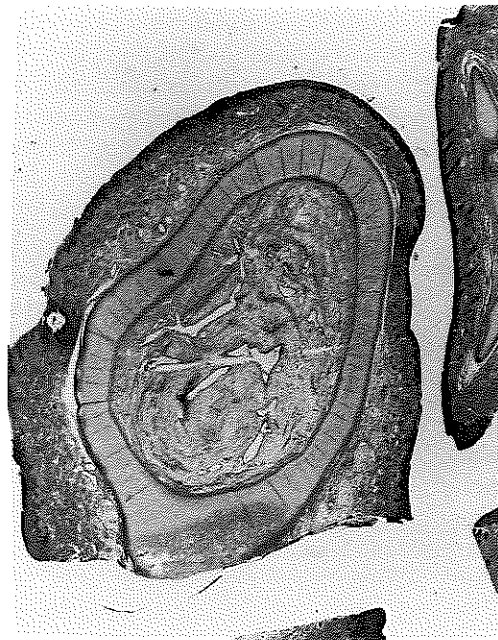

Fig 2. Low-power photomicrograph of Armed Forces Institute of Pathology case of "pharyngeal hairy polyp" (ie, accessory auricle) with section through circular plate of cartilage with thickness similar to that of normal auricular cartilage.

the histologic appearance of the dermoid polyps to the appearance of fetal auricles confirmed the general resemblance of the polyps to auricles.

Although the cases of congenital nasopharyngeal teratomas contained cartilage, extensive well-formed plates of uniform thickness resembling auricular cartilage were not seen. The cartilage was generally more cellular and immature in appearance than was the cartilage found in the dermoid polyps. There was one small focus in one case that manifested elastic fibers, but the other, larger areas of cartilage in this case did not.

DISCUSSION

The hypothesis that pharyngeal dermoid (hairy) polyps are actually accessory auricles was generated by pondering a few simple observations. The term dermoid generally connotes a dermoid cyst, which usually is thought to probably develop from an inclusion, or entrapment, of ectodermal tissue with the capacity to form skin.^{15,16} With respect to the pharyngeal dermoids, this concept presents two main difficulties, both of which serve as clues that these lesions are something a bit different from the usual dermoid. First, they are solid, exophytic masses, and second, they are not close to a cutaneous site. The solid, exophytic growth does not suggest a developmental inclusion or entrapment phenomenon. Their not being close to a cutaneous site presents a significant problem for explaining the embryogenesis of these

polyps, although it has not seemed to be a problem to other authors.¹⁷ Since these lesions are not far from the ectodermally derived mucosa of the mouth or nasal cavity, other authors have related these areas to the development of dermoid polyps. However, lesions similar to pharyngeal dermoid polyps do not seem to occur in the sinonasal or oral mucosa. Dermoid cysts of the nasal bridge (aside from being cysts and not solid polyps) are related to and derived from a cutaneous area, not the schneiderian mucosa. Dermoid cysts or polyps of the nasal cavity proper or the paranasal sinuses are virtually unknown. Although dermoid cysts of the floor of the mouth are well known, these lesions possibly could be derived from midline upper neck or submental cutaneous areas rather than from stomodeal ectoderm. In any case, they are cysts rather than exophytic polyps. Most persons have tiny nests of sebaceous glands (Fordyce granules) in the oral cavity, and these structures are derived from oral cavity mucosa. However, they do not form gross polypoid masses.

If pharyngeal dermoid polyps are ectopically located malformations derived from sinonasal or stomodeal ectoderm, it seems quite unusual that similar lesions do not seem to form "nonectopically" in the sinonasal or stomodeal areas. This is unusual enough, in our thinking, that we strongly doubt the origins of these lesions postulated in the literature as possibly being from inclusions between palatal shelves¹⁷ or remnants of the breakdown of the buccopharyngeal membrane.¹⁸ If they are not from these areas (and if not teratomas), what would be the embryologic provenance of these lesions?

There is one area, other than the mouth or nasal cavity, in which the endodermal upper pharyngeal tissue is developmentally close to ectodermal tissue — indeed, very close. The first pharyngeal branchial pouch endoderm is usually said to contact the first branchial groove ectoderm (in the area that will ultimately develop into the tympanic membrane), and subsequently the two layers "pull away" as some mesodermal tissues develop between them. This seems the most plausible area for displacement of ectodermal tissue that subsequently becomes associated with the tympanum, eustachian tube, or pharynx. We believe this is indeed the origin of pharyngeal dermoid polyps, because of the additional evidence that indicates an auricular quality for the tissues of the dermoid polyps, and since, of course, the normal auricle develops around the first branchial cleft (from the ectoderm of the cleft and the adjacent first and second arch mesoderm).

Additional evidence is derived from the spectrum of exact locations of dermoid polyps. Most are in the

nasopharynx and located laterally. This is not far from the eustachian tube. Some arise from the eustachian tube and project into the nasopharynx.⁸ Eustachian tube origin may be more common than is reported, because the origin from the tube orifice may not be explicitly determined clinically in some cases.⁸ Rare examples have been confined to within the tube proper.¹⁰ Finally, there are instances of dermoid polyps within the middle ear space (as reported herein), some of which appear to be arising from the tube.¹² This spectrum of locations for dermoid polyps strongly suggests an association with the first pharyngeal pouch, from which the eustachian tube develops.

What about the significant number of pharyngeal dermoid polyps that appear to arise from the nasopharyngeal side of the soft palate or from the faucial tonsillar area and thus are not next to the eustachian tube orifice? Does this argue against a first pharyngeal pouch relationship? Not significantly, since these areas are still related to the endodermal pharyngeal branchial apparatus. A dermoid polyp in the tonsillar area seems hardly significantly "ectopic" from the first pouch area, when it is recalled that the caudal border of the first pouch (and cleft) is the second arch and that the tonsillar area is related to the second arch. Dermoid polyps of the tonsillar area are discussed in the literature as probably of second branchial cleft origin. It would be more accurate to include the second arch in this proposed origin, since these solid polyps surely include arch mesoderm in their formation, and the second arch is also involved (in part) in the formation of the auricle. It is true that tonsillar dermoid polyps would seem to be more related to the second branchial apparatus than to the first, but this probably is not sufficient reason to separate them as something fundamentally different from the nasopharyngeal dermoids. After all, external cutaneous accessory auricles (auricular tags) can be located well down on the neck, significantly away from the auricle and perhaps more in a second cleft area, and yet no one suggests considering them a different type of lesion from a histologically identical one located closer to the auricle. Tonsillar dermoid polyps are histologically identical to external auricular tags, and they are probably related lesions.

Important support for the hypothesis that pharyngeal dermoid polyps are accessory auricles is provided by the characteristics of the cartilage found in many of them. The first important point has already been documented in several reports,^{5,6} and this is the fact that some of these lesions grossly resemble malformed auricles. This resemblance includes an extended plate of cartilage of uniform thickness that grossly very much resembles auricular cartilage.

However, another important aspect of this cartilage has not been discussed in the literature. Some of these lesions have strikingly elastic cartilage, as did the tympanic dermoid polyp reported herein (Fig 1C) and one of our pharyngeal cases. The cartilage in one of the cases reported by Chaudry et al¹⁴ (their Figure 6) is similar, and one can discern elastic fibers from the illustration even without the benefit of color or a special elastic tissue stain. The reason this is important is that well-developed elastic cartilage is not found in many areas of the body. Aside from the external ear and eustachian tube, the only other areas with appreciable elastic cartilage are the epiglottis and portions of the nasal alae. Thus, the presence of well-developed elastic fibers in some cases of pharyngeal dermoid polyps makes the cartilage identical in every respect to auricular cartilage and very strongly supports the developmental relationship to the ear. This striking finding is probably the most important factor that indicates that these developmental anomalies are choristomatous accessory auricles.

The striking and extensive elastic tissue in some of these lesions is also an argument against their representing meager teratomas. Since elastic cartilage is so specialized and sparse in the body, one would not expect to find much elastic cartilage in teratomas in general, and indeed, this is the case. There was one small focus with elastic fibers in one of the AFIP nasopharyngeal teratomas, but in most teratomas this is not a finding. Also, most of the cartilage in the AFIP nasopharyngeal teratomas was more cellular and more immature in appearance compared to the cartilage in the dermoid polyps, and the overall appearance of the cartilage in these two types of lesions was quite different.

After having had the opportunity to see many unusual examples of head and neck disease over a period of 16 years, the senior author (D.K.H.) believes that classifications of pathologic conditions are almost certain to fail to easily classify or explain all the conditions one will encounter. The multitudinous variations of the manifestations of disease do not always fit into the categorical drawers constructed by the pathologist. This is particularly true of the wondrous spectrum of biologic variability manifested in developmental abnormalities.¹⁹ Nature does not always entirely cooperate with the dividing lines of our diagnostic categories and terms. Thus, we do not claim to be able to obviously and clearly explain by the hypothesis of this paper every example of a pharyngeal lesion containing skin. It is possible that rare examples of pharyngeal dermoids are meager teratomas. For example, the case described by Aughton et al²⁰ seems to mostly fit the category of dermoid (hairy) polyp, but it was said to contain a small

amount of primitive neural and mesenchymal tissue. We do claim, however, that the features of almost all pharyngeal dermoid polyps as a group constitute a type of lesion that is different enough from the usual teratoma in tissue composition and probable developmental genesis that it should be categorized as different from a teratoma. If the term teratoma is to maximally retain its useful connotations, it should not become overly broad in scope. Accordingly, an accessory auricle (or auricular tag) on the skin of the neck is not classified as a teratoma. Certainly, accessory auricles on the neck do not contain structures from all three embryonic germ layers (the endoderm is missing), nor do they have as much tissue heterogeneity as do most teratomas. Except for not being located on a cutaneous site, we believe pharyngeal dermoid polyps are essentially the same type of developmental anomaly as cervical accessory auricles.

Although rare teratomas of the temporal bone area exist,²¹ it is likely that many of the lesions of the middle ear or eustachian tube that have been reported as teratomas are actually accessory auricles (dermoid polyps). On the other hand, some middle ear dermoids seem to actually be dermoid cysts¹³ and in the strictest sense might not be accessory auricles. The external ear canal develops from the first branchial cleft, and developmental anomalies that recapitulate this process can form subcutaneous dermoid cysts and sinuses. Occasionally, one of these might form in such a way as to present mainly as a middle ear lesion. But the solid and polypoid dermoid lesions of the middle ear, eustachian tube, and pharynx develop, we believe, from embryological displacements of first and second arch tissue with "auricular hillock" potential (from which the auricle develops), and these lesions are appropriately considered to be, and should be labeled as, accessory auricles.

REFERENCES

1. Arnold J. Ueber behaarte Polypen der Rachen-Mundhoehle und deren Stellung zu den Teratomen. *Virchows Arch Pathol Anat Physiol* 1888;111:176-202.
2. Schwalbe E. *Die Morphologie der Missbildungen*. Vol 2. Jena: Gustav Fischer, 1907.
3. Sexton M. Hairy polyp of the oropharynx: a case report with speculation on nosology. *Am J Dermatopathol* 1990;12:294-8.
4. Tharrington CT, Bossen EH. Nasopharyngeal teratomas. *Arch Pathol Lab Med* 1992;116:165-7.
5. Kanzaki S, Yamada K, Fujimoto M, Arata A, Miyake M, Ohbayashi K. So-called hairy polyp resembling an auricle. *Otolaryngol Head Neck Surg* 1988;99:424-6.
6. Schuring AG. Accessory auricle in the nasopharynx. *Laryngoscope* 1964;74:111-4.
7. Fried MP, Vernick DM. Dermoid cyst of the middle ear and mastoid. *Otolaryngol Head Neck Surg* 1984;92:594-6.
8. Nicklaus PJ, Forte V, Thomer PS. Hairy polyp of the eustachian tube. *J Otolaryngol* 1991;20:254-7.
9. Prescott CAJ. Two cases of neonatal nasopharyngeal teratoma. *Am J Otolaryngol* 1993;14:211-3.
10. Pirodda E. Dysontogenetic dermoid of the eustachian tube. *J Laryngol Otol* 1965;79:546-53.
11. Boedts D, Moerman M, Marquet J. A hairy polyp of the middle ear and mastoid cavity. *Acta Otorhinolaryngol Belg* 1992;46:397-400.
12. Eichel BS, Hallberg OK. Hamartoma of the middle ear and eustachian tube. *Laryngoscope* 1966;76:1810-5.
13. Howie TO. A case of dermoid or developmental cyst of the middle ear cavity. *J Laryngol Otol* 1962;76:60-6.
14. Chaudhry AP, Lore JM, Fisher JE, Gambrino AG. So-called hairy polyps or teratoid tumors of the nasopharynx. *Arch Otolaryngol* 1978;104:517-25.
15. New GB, Erich JB. Dermoid cysts of the head and neck. *Surg Gynecol Obstet* 1937;65:48-55.
16. White H. Dermoid tumours of soft palate. *Br Med J* 1881;1:597.
17. Eggston AA, Wolff D. *Histopathology of the ear, nose and throat*. Baltimore, Md: Williams and Wilkins, 1947:814.
18. Badrawy R, Fahmy SA, Taha AM. Teratoid tumours of the nasopharynx. *J Laryngol Otol* 1973;87:795-9.
19. Willis RA. Some unusual developmental heterotopias. *Br Med J* 1968;3:267-72.
20. Aughton DJ, Sloan CT, Milad MP, Huang TE, Michael C, Harper C. Nasopharyngeal teratoma ("hairy polyp"), Dandy-Walker malformation, diaphragmatic hernia, and other anomalies in a female infant. *J Med Genet* 1990;27:788-90.
21. Silverstein H, Griffin WL, Balogh K Jr. Teratoma of the middle ear and mastoid process. *Arch Otolaryngol* 1967;85:243-8.